Peptic ulcers and their complications

Duncan J Stewart

Roger Ackroyd

Abstract

The incidence and management of peptic ulcer disease have changed considerably since the first surgical interventions, carried out less than a century ago. Operative techniques refined during the early second half of the 20th century have become almost obsolete in today's practice for two principal reasons. Firstly, understanding of the aetiology of the disease process has taken a dramatic step forward with the discovery of *Helicobacter pylori* now known to be associated with 95% of cases of duodenal ulceration. Secondly, the pharmacological development of H_2-receptor antagonists and more recently proton pump inhibitors mean that the control of acid secretion in the stomach is now achievable without resorting to invasive and often debilitating surgical procedures. Despite these advances, emergency presentations with either haemorrhage or visceral perforation continue to occur with relative frequency and it remains the responsibility of the surgical trainee to understand the fundamentals of patient management in these situations.

Keywords aetiology; complications; *Helicobacter pylori*; management; peptic ulcer disease

Introduction

The incidence of peptic ulceration has decreased dramatically over the past 30 years.[1] This is largely due to the improvement in pharmacological management of dyspeptic symptoms and a greater understanding of the aetiology. Whereas surgery was previously a frequent solution for chronic peptic ulcer disease,[2] this is now almost exclusively reserved for the emergency situation and in the case of haemorrhage, only after endoscopic, and increasingly radiological intervention have failed. This review will examine the common aetiological elements of peptic ulcer disease, how the pathological process occurs, and medical and surgical management strategies for the condition.

Aetiology and pathophysiology of peptic ulceration

Several factors are known to be involved in the development of gastric and duodenal mucosal injury (Box 1). Of these, the use of non-steroidal anti-inflammatory drugs (NSAIDS) and infection with *Helicobacter pylori* play by far the biggest roles.

The reporting of the *Campylobacter*-like organism *H. pylori*, by Warren and Marshall in 1984[3] marked a giant leap in medical understanding of peptic ulceration. This Gram-negative, helical, microaerophilic, flagellated bacterium has since been recognized to be responsible for up to 95% of duodenal and 70% of gastric ulcers.[4] Furthermore, it is present in up to 10% of patients with dyspepsia without ulceration. Infection with *H. pylori* is widespread and probably acquired in childhood via the faecal–oral route, although this is yet to be confirmed. In addition, socioeconomic status appears to be inversely related to the prevalence of infection.[5] *H. pylori* colonizes only gastric mucosa, predominantly in the antrum and pyloric canal. It possesses a urease enzyme which converts urea to ammonia and carbon dioxide, buffering gastric acid in its vicinity facilitating its survival in the acidic gastric environment.

There are a number of mechanisms by which *H. pylori* is capable of producing an injurious effect on the gastric mucosa. On initial infection, there is a period of hypogastrinaemia and reduced gastric acid secretion. Following this, the alkaline environment produced by *H. pylori* has an inhibitory effect on antral D cells, reducing somatostatin secretion, which prevents the inhibition of gastrin secretion by antral G cells leading to hypergastrinaemia, parietal cell hyperplasia and increased gastric acid secretion. In duodenal ulceration, duodenal mucosal metaplasia produces areas of ectopic gastric mucosa. *H. pylori* is then able to colonize the duodenum, heralding a marked decrease in acid-stimulated bicarbonate release, leading to a 50-fold increase in the risk of developing a duodenal ulcer.[6] Some of this increased risk may be attributed to the ability of *H. pylori* to variably and reversibly block secretin release from the mucosal cells of the duodenum.[7] Secretin acts to raise the pH of fluid in the duodenum through the slowing of gastric emptying, reducing gastric acid secretion and by stimulating the secretion of bile, mucous and pancreatic exocrine fluid, all of which are of alkali pH. The end result is abnormal acidification of duodenal contents. In addition to these mechanisms, *H. pylori* is capable of

Causes of peptic ulceration

Infection — *Helicobacter pylori*
Drugs — Non-steroidal anti-inflammatory drugs (including aspirin)
Steroids
Bisphosphonates
Immunosuppressants
Cocaine
Stress — Psychological
Physical — burns (Curling's ulcer)
Head injury (Cushing's ulcer)
Tobacco smoking
Alcohol intake
Zollinger–Ellison syndrome (Gastrinomas)
Age-related decline in prostaglandin levels

Box 1

Duncan J Stewart *MD FRCS is a Specialist Registrar in the Department of Upper Gastrointestinal Surgery at Sheffield Teaching Hospitals, NHS Foundation Trust, UK. Conflict of interest: none declared.*

Roger Ackroyd *MD FRCS is a Consultant Surgeon in the Department of Upper Gastrointestinal Surgery at Sheffield Teaching Hospitals, NHS Foundation Trust, UK. Conflict of interest: none declared.*

Mechanisms of *Helicobacter pylori*-associated peptic ulceration

Direct local effects	Toxin release (vacA, cagA)
Effects on immune response	Release of cytokines (esp. interleukin-8)
	Recruitment of inflammatory cells and mediators
Effect on acid secretion	Hypochlorhydria → hyperchlorhydria
	Hypergastrinaemia
	Reduced somatostatin levels
	Reduced secretin levels
	Parietal cell hyperplasia (gastric ± duodenal)
Effect on duodenal secretion	Reduced secretin
	Reduced bicarbonate

Table 1

toxin production, release of cytokines (especially interleukin (IL)-8) and recruitment of inflammatory cells with production of further inflammatory mediators (Table 1).

NSAID use is thought to be the most common cause of gastrointestinal (GI) mucosal injury in the Western world.[1] The effects of NSAIDs occur through the inhibition of cyclo-oxygenase (COX)-1, preventing the synthesis of prostaglandins (PG). The result of this inhibition leads to decreased intra-gastric mucous production and blood flow, thereby reducing the normally protective mucosal barrier and also reducing the ability of mucosal cells for repair.

Clinical presentation and diagnosis

Patients suffering with peptic ulceration can present acutely unwell as a medical or surgical emergency, or with more chronic symptoms. Acutely, patients often present with severe pain which may be an exacerbation of discomfort with which they have suffered for many months or even years. Alternatively, they may present with a complication of peptic ulceration. For example, haematemesis or melaena from ulcer erosion into a blood vessel, peritonitis from gastric or duodenal perforation or even profuse vomiting due to gastric outlet obstruction from duodenal stenosis, although this is unusual today.

The diagnosis of peptic ulcer disease is frequently a clinical one, although gastric and duodenal ulceration are indistinguishable by symptoms alone. The patient is likely to have upper abdominal pain which is often gnawing and may be felt in the back. It often has its own periodicity and may disappear for months at a time. On occasion, eating may relieve the discomfort. A past medical history may indicate some precipitating factor and a comprehensive drug history is particularly important. Unless suffering a complication, clinical examination is often unremarkable save for a variable degree of upper abdominal discomfort on palpation.

Once the diagnosis of peptic ulceration is suspected, the first-line investigation of choice is an oesophagogastroduodenoscopy (OGD). This will allow mucosal inspection of the upper GI tract lumen. Lesser curve ulceration is the most common site within the stomach, but duodenal ulceration is more common overall and most frequently seen in the 1st part of the duodenum. During the endoscopic procedure consideration should be given to the detection of *H. pylori* within the stomach. The diagnosis of its presence can be achieved in several ways, detailed in Table 2, but most common is a rapid urease test performed by placing a tissue biopsy from the gastric antrum into a small well of a pH-sensitive gel containing urea. If *H. pylori* organisms are present, the urease enzyme breaks down the urea to form alkaline ammonium ions that lead to a rise in pH within the gel and a corresponding change in colour. Of the non-invasive tests, the urea breath test once again exploits the ability of *H. pylori* to metabolize urea into more basic components. Briefly, the patient drinks a solution containing a known quantity of ^{13}C- or ^{14}C-radiolabelled urea. In the presence of viable *H. pylori* organisms,

Methods of detection of *Helicobacter pylori*

Test	Advantages	Disadvantages
Histological identification	Considered the gold standard	Requires tissue sample Relatively costly and labour intensive
Microbiological culture	By definition 100% sensitive and specific	Requires tissue sample More costly and labour intensive Difficult to culture
Urease breath test	95% sensitivity and specificity Reliable indicator of active infection	Need to stop antibiotics and antacid medications prior to taking Relatively labour intensive
Rapid urease test (e.g. CLO test®)	Easy to do at endoscopy Quick result Sensitivity 93%, specificity 96%	A few false-positives Requires endoscopy
Serology for *H. pylori* antigen	Non-invasive Sensitive for infection	Less specific (many false-positives) as may have prior exposure but no active infection
Stool antigen test	Sensitivity and specificity 92%	Need to stop antibiotics and antacids several weeks prior to test

Table 2

this is converted to ammonium ions and carbon dioxide, which is transported to the lungs, collected as exhaled breath and analysed by mass spectrometry or liquid scintillation counting, to give a ratio of the ^{13}C- or ^{14}C-radiolabelled carbon dioxide to the naturally occurring ^{12}C-carbon dioxide.

Medical management of uncomplicated peptic ulcer disease

The majority of patients with peptic ulcer disease can now be treated perfectly well with medication. This was not always the case. Previously, peptic ulcer disease was predominantly managed using a number of surgical techniques with invariably high morbidity and mortality rates.[1] However, the development of histamine (H_2)-receptor antagonists in the 1970s led to a dramatic shift, with rates of elective ulcer surgery decreasing by up to 80% in the 1980s.[1] Medical treatment was improved further in the late 1980s when the proton pump inhibitor (PPI) omeprazole was introduced. Although H_2-receptor antagonists are effective at reducing acid secretion, with treatment leading to the healing of 80–90% of peptic ulcers, they do not block it completely as gastrin and vagal stimulation can still induce parietal cell acid secretion. However, the H^+/K^+-ATPase pump situated on the apical membrane of the gastric parietal cell provides a common end to the acid secretion pathway and is completely and irreversibly inhibited by PPI medication, which leads to faster ulcer healing in a greater percentage of patients than relying on H_2-receptor antagonists alone.[2]

The National Institute for Health and Clinical Excellence (NICE) has produced a clinical guideline for the management of patients with dyspeptic symptoms in primary care (CG17).[8] The focus of these guidelines is treatment with a proton pump inhibitor, together with testing for the presence of *H. pylori* and subsequent antimicrobial eradication therapy as appropriate (Table 3). Also included should be an assessment of long-term medication to identify potentially ulcerigenic drugs and lifestyle advice on alcohol intake, smoking and weight loss. CG17 is currently in the early stages of a review process; for updates the reader is referred to http://guidance.nice.org.uk/CG17.

Management of acute complicated peptic ulcer disease

Patients can present having had no previous treatment for their peptic ulcer disease, or they may find themselves in the unusual situation where pharmacological treatment has failed. The two most commonly encountered complications are bleeding and perforation, with annual incidence estimates of 19.4–57.0 and 3.8–14.0/100,000 population, respectively.[9] More often than not, both conditions will leave the patient requiring urgent medical or surgical intervention and despite a variety of techniques, there exists a significant risk of 30-day mortality (8.6% and 23.5% respectively).[9]

The presentation of acute haemorrhage from the upper GI tract with haematemesis or melaena can be an overwhelming sight for the uninitiated and is frequently distressing for the patient. The first priority is to begin active resuscitation with the goal to achieve haemodynamic stability. Although ulcers account for 60% of upper GI haemorrhage, erosions only are seen in approximately 25% of patients. Other, more unusual causes include a Mallory–Weiss injury to the oesophagus, oesophageal varices, bleeding from a tumour, aorto-enteric fistula (particularly in those who have had prior abdominal aortic surgery) or congenital arterio-venous malformations (Dieulafoy's disease). With the exception of suspected aorto-enteric fistula (where the first-line investigation should be a CT angiogram), these patients should undergo urgent OGD for diagnostic and potentially therapeutic purposes. Recent guidelines from the Scottish Intercollegiate Guidelines Network (SIGN) have been adopted in England by the British Society of Gastroenterology (BSG) for the management of patients presenting with acute upper gastrointestinal haemorrhage.[10] These patients should ideally be treated within a dedicated service with interventional endoscopy available 24 hours a day. It is recommended that all patients undergo endoscopic assessment within 24 hours of presentation and that treatment with PPI medication is not used until after the initial endoscopy as their use prior to OGD may downstage any visualized lesion[11] or lead to fewer patients having evidence of recent haemorrhage.[12] There are numerous endoscopic options in the management of bleeding peptic ulceration. Focussed injection with vasoconstrictors (adrenaline), application of haemostatic clips, endoscopic heater probes, argon photocoagulation and laser probes have all been used with varying degrees of success. Once the endoscopic intervention is completed, the use of pharmacological proton pump inhibition has become critical in the management of these patients. Proton pump inhibition has been shown to be more effective than H_2-receptor antagonists in reducing not only re-bleeds, but also the need for surgical intervention and overall mortality.[11,13] Although infrequently used, there is some evidence that the anti-fibrinolytic agent, tranexamic acid, may produce a reduction in all-cause mortality

Current recommended eradication therapy for symptomatic *Helicobacter pylori* infection (taken from *BNF* 61, March 2011)

Acid suppression	Antibacterial medication		
	Amoxicillin	Clarithromycin	Metronidazole
Twice-daily dose of any PPI	1 g twice daily	500 mg twice daily	–
	–	250 mg twice daily	400 mg twice daily
	1 g twice daily	–	400 mg twice daily

If the patient is allergic to penicillin, or has had a recent course of either metronidazole or a macrolide antibiotic, then the alternative should be used in combination with a proton pump inhibitor (PPI) for 7 days. Expect 85% eradication of *H. pylori* with these regimens.

Table 3

without a significant increase in thromboembolic events.[14] Despite all of these options, bleeding from peptic ulcers will stop spontaneously in 70–80% of patients.[6] Should re-bleeding occur following endoscopic intervention, the patient should undergo repeat endoscopic assessment with a further attempt at haemostasis. This has been shown to reduce consequent morbidity when compared to surgical intervention.[15] Further still, when endoscopic therapy fails to control haemorrhage there is increasing evidence that selective arterial embolization should be the option of choice prior to surgical intervention, with high reported technical and clinical success rates,[16] even if there is no angiographically evident contrast extravasation.[17] A downward trend in 30-day mortality comparing embolization to surgery has been observed.[18] An overall summary of the management strategy is shown in Figure 1.

Perforated peptic ulcers are now most commonly seen in elderly patients, particularly women, the majority of which are attributable to NSAID use.[5] A history of sudden onset of upper abdominal pain alongside clinical signs of sepsis and even shock may be apparent. However, with a small leak, or a perforation into the lesser sac from the posterior wall of the stomach, the signs may be a great deal more subtle and a high index of suspicion is required. Only approximately 50% of patients will have visible sub-diaphragmatic gas on a plain erect chest X-ray (Figure 2) and the serum amylase may be raised, although rarely to the extent of that found in a patient with acute pancreatitis. In cases of diagnostic difficulty, and if the patient is well enough, CT is invariably diagnostic. The patient should be resuscitated and prepared for theatre, except in a few remarkable circumstances, for example overwhelming septic shock combined with pre-existing frailty or if the patient is well with minimal symptoms, and then a trial of conservative management with nasogastric tube drainage and intravenous antibiotics may be considered. The principles of operative intervention are to cover or close the ulcer defect and thorough peritoneal lavage to reduce peritoneal contamination with gut luminal contents. This is most often achieved through an upper midline incision, covering of the defect with an omental patch; a technique first described by Graham in 1937.[2] If the edges of the ulcer can themselves be brought into apposition, then so much the better.

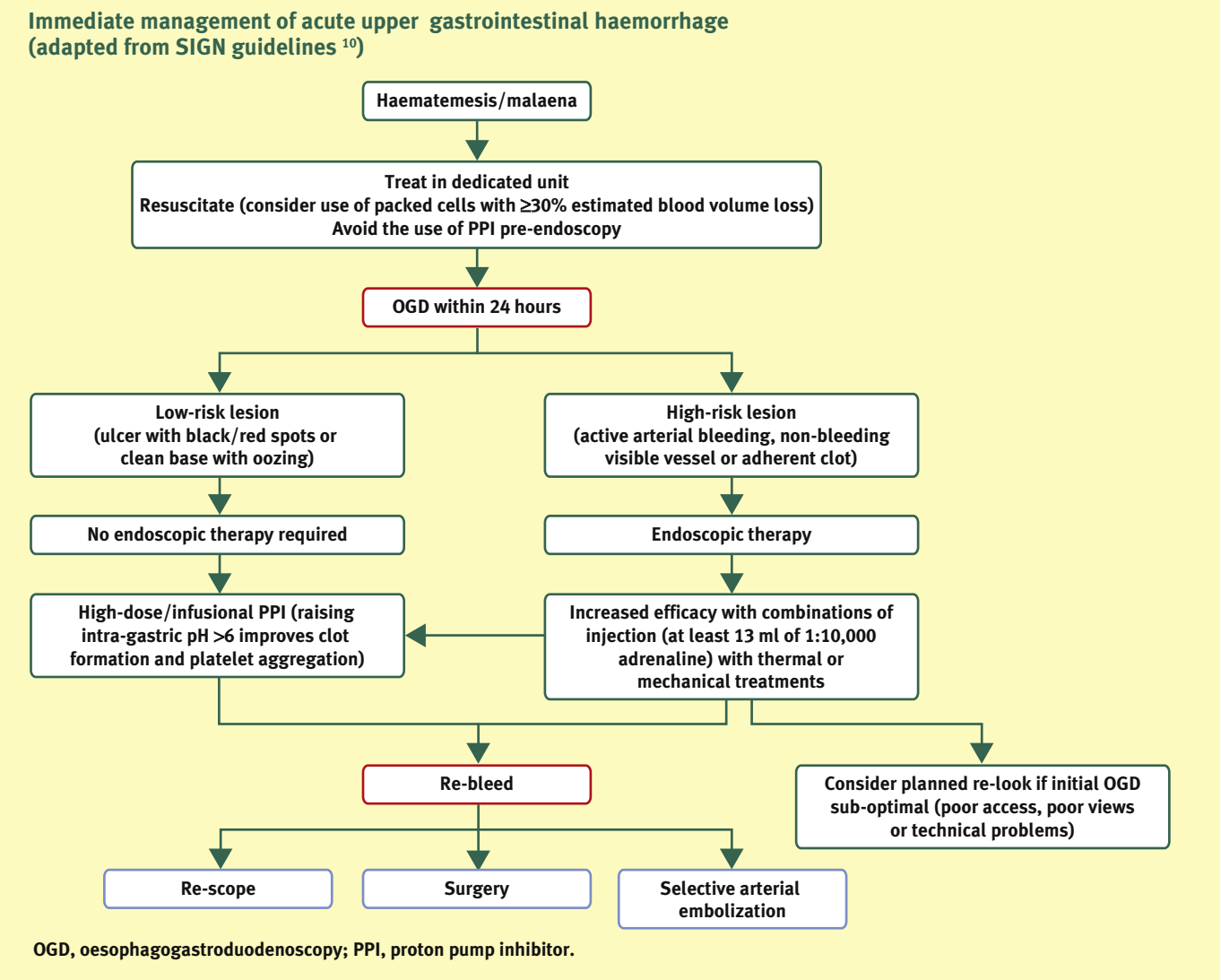

Figure 1

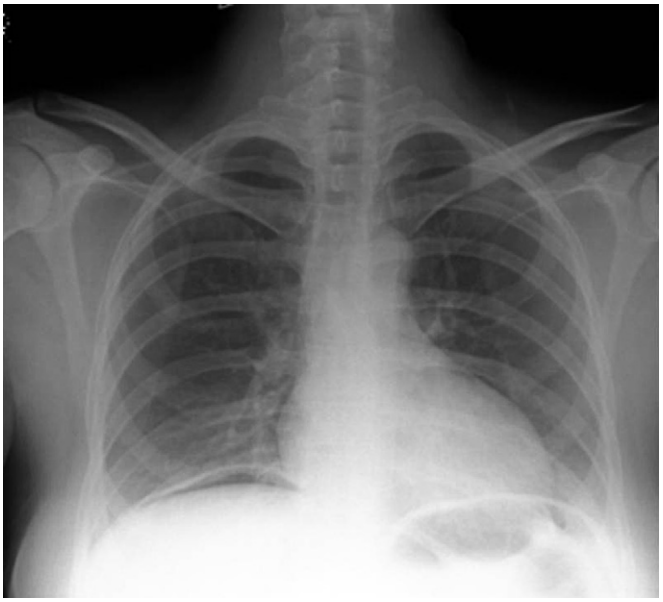

Figure 2 Free sub-diaphragmatic gas on erect postero-anterior chest X-ray.

Despite a deceptively simple concept, surgical repair of perforated peptic ulceration is associated with high levels of morbidity and mortality.[9] Preoperative factors associated with higher mortality include shock on admission, metabolic acidosis, tachycardia, acute renal failure, low serum albumin, high American Society of Anaesthesiologists (ASA) score and a preoperative delay of more than 24 hours.[19] A recent multicentre randomized controlled trial (RCT) has demonstrated that the introduction of a multidisciplinary and multi-modal perioperative care protocol can significantly reduce 30-day mortality (by more than one-third), although it still remained 17%.[20] Based on benefits seen across many types of surgical procedures an increasing number of surgeons are approaching this condition employing minimal access techniques. Although no consensus,[21] in general terms the approach is similar to that of the open procedure. A Cochrane review in 2005 concluded that both open and laparoscopic approached were not significantly clinically different, although concerns were expressed about the available evidence for comparison.[22] A more recent systematic review, analyzing data from 56 studies has concluded that a laparoscopic approach is associated with significantly less postoperative pain, a reduction in morbidity, less mortality and a shorter hospital stay. However, they acknowledge that operating times remain longer and there is a greater risk of recurrent leakage at the repair site. They recommend that patients over the age of 70 years with symptoms persisting for more than 24 hours should not be considered candidates for laparoscopic repair.[21] In the surgical management of either bleeding or perforation, it must never be forgotten that if a gastric ulcer is discovered, it must either be excised or biopsied at operation to exclude malignant transformation.

Surgical management of chronic complicated peptic ulcer disease

The surgical management of peptic ulcer disease has a long and illustrious history. As mentioned previously, prior to the 1980s and the introduction of H_2-receptor antagonists and PPIs large numbers of patients underwent surgical procedures for chronic peptic ulceration associated with complications such as gastric outlet obstruction most often due to duodenal stenosis with fibrotic scar tissue or chronic, intractable pain.

Theodor Billroth, Professor of Surgery in Vienna late in the 19th century, pioneered gastric resection for carcinoma of the stomach. Techniques developed in his department became important in the management of chronic peptic ulcer disease. The Billroth I procedure consists of a distal gastric resection and a gastroduodenal anastomosis, retaining the physiological and anatomical gastroduodenal pathway (Figure 3a).[23] In those patients who may not be well enough to withstand the insult of a partial gastrectomy, a lesser technique was developed to allow drainage of the stomach, bypassing the distal narrowing. A loop of jejunum can be anastomosed usually onto the posterior wall of the stomach, to maximize dependent drainage, forming a gastrojejunostomy. The loop may pass via the ante-colic or retro-colic route. The combination of a distal gastrectomy as in the Billroth I procedure and a reconstruction anastomosis as per the gastrojejunostomy forms the basis of the Billroth II procedure (Figure 3b) which has been employed when it as proven impossible to perform the gastroduodenal anastomosis. The procedure is effectively identical to the Polya operation, although over the years surgeons have modified the technique, using a longer afferent loop of jejunum in an attempt to prevent kinking and a consequent 'blow-out' of the duodenal stump.

The role of vagal innervation to the stomach was elucidated in the early part of the 20th century. It became apparent that

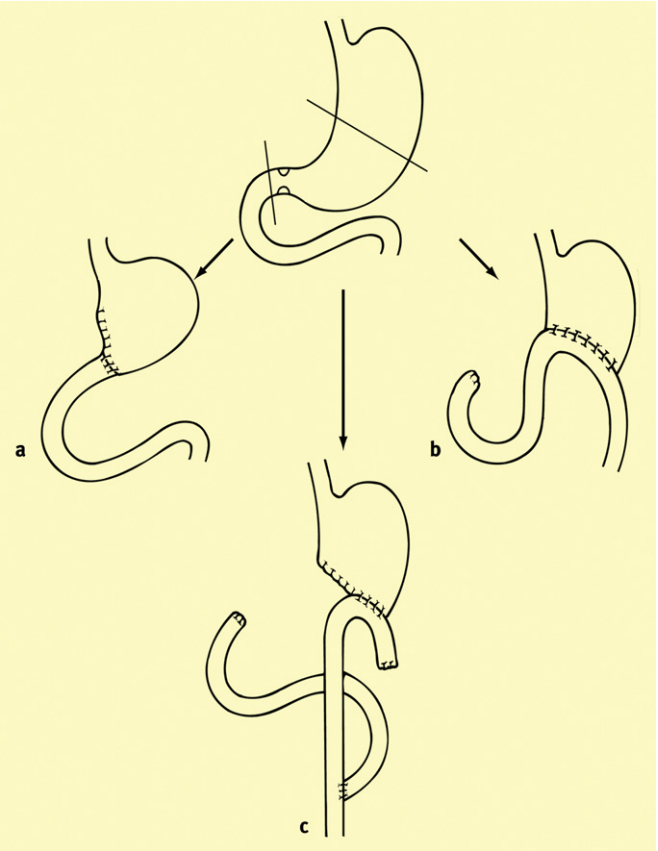

Figure 3 Schematic representations of a distal gastric resection and the reconstructions of the Billroth I. (**a**) Billroth II/Polya (**b**) procedures and Roux-en-Y (**c**).

although vagal division would reduce acid secretion in the stomach, it also leads to gastric atony and markedly delayed gastric emptying. With this in mind, a drainage procedure was combined with interruption of vagal supply. Two German surgeons, Walter Heineke and Johann von Mikulicz independently developed a procedure involving a linear incision across the pylorus and a transverse closure in either one or two layers, onto which some surgeons add a layer of omentum, now well known as the Heineke–Mikulicz pyloroplasty.[2,23] For duodenal ulceration, the procedure of truncal vagotomy and pyloroplasty was introduced. Surgery to refine this procedure progressed to the selective vagotomy, which preserved the hepatic and ceoliac branches but completely denervated the stomach. Further to this, the highly selective or parietal cell vagotomy was developed in the late 1960s by David Johnson, Professor of Surgery in Leeds. The aim was to divide the branches of the anterior and posterior nerves of Latarjet, so completely denervating the parietal cells but preserving motor innervation of the antrum, known as a highly selective vagotomy. This precluded the need for a gastric drainage procedure and reduced gastric acid secretion by 65–75%.[6] Unfortunately, despite the best attempts all of these procedures, both resections and denervation were associated with a risk of ulcer recurrence. Some were associated with a greater risk than others, for example, a gastrojejunostomy performed as a drainage procedure only places the jejunum in direct contact with gastric acid and ulceration is seen in up to 50% of cases.[6] At the other end of the spectrum, a highly selective vagotomy carried out by an experienced surgeon should have a re-ulceration rate no higher than 5%.[2]

Effects of peptic ulcer surgery

Unfortunately, many of the operations described have significant sequelae associated with them causing varying degrees of morbidity. Recurrent ulceration as already been mentioned, but represents less of a problem with the pharmacological advances that have been made, in addition to the understanding of the role of *H. pylori*. Early satiety is a common symptom after all procedures, due either to a physically small stomach after resection, or a failure of relaxation following vagotomy. As well as the effects described above, truncal vagotomy leads to biliary stasis and therefore makes the development of gallstones much more likely.

Bile reflux

Any procedure which interferes with the function of the pylorus will leave a patient at risk of bile reflux and vomiting. A patient may suffer with pain and reflux symptoms which are often precipitated by eating. Depending on the initial procedure, the patient may eventually need revisional surgery with the conversion to a Roux-en-Y reconstruction (Figure 3c) to reduce the volume of bile reflux.

Diarrhoea

Most patients suffer some degree of loose motions following surgery form peptic ulceration, but in approximately 5% it can be life-altering diarrhoea. It is likely to be due to the combination of rapid gastric emptying with the creation of large volumes of liquid chyme, combined with altered small bowel motility due to vagal interruption. It is difficult to treat and anti-diarrhoeal drugs may be the only options.

Dumping

Many consider that the mechanisms leading to diarrhoea are the same ones that cause dumping. The syndrome of dumping can be divided into early and late. Early dumping affects about 10% of patients after peptic ulcer surgery and leads to faintness, palpitations, sweating and abdominal discomfort almost immediately after eating. It is due to a high volume of osmotically active food moving rapidly into the small bowel leading to the sequestration of circulating fluid into the gut. Patients tend to get some relief from lying down and they can be reassured that the situation often improves with time. The somatostatin analogue, octreotide has been used with some effect, but occasionally patients will need revisional surgery and once again, conversion to a Roux-en-Y reconstruction often leads to a resolution of symptoms. Late dumping is due to hypoglycaemia and the patient experiences a lot of the same symptoms, but it tends to occur 30 minutes after eating. The rapid carbohydrate load, leads to a rise in serum glucose, which leads to a rise in insulin secretion. Patients can relieve the symptoms by a sugary drink or sweet, but octreotide is also very effective.

Malignant transformation

All procedures designed to treat the complications of peptic ulcer disease are associated with an increased risk of the development of gastric cancer, except for highly selective vagotomy. The risk is thought to be up to four times that of the general population and the lag phase is often 10 years or more.

Nutritional consequences

Acid in the stomach is instrumental in the conversion of ferric (Fe^{3+}) iron to ferrous (Fe^{2+}) iron, enabling its uptake in the ileum. Iron-deficiency anaemia may result as a consequence of surgery for peptic ulcer disease. In addition, particularly in those who have had extensive gastric resections, the lack of intrinsic factor produced by parietal cells leads to the failure of receptor-mediated uptake of vitamin B_{12} in the terminal ileum.

Summary

The development of H_2-receptor antagonists and PPIs has revolutionized the management of peptic ulceration. There are now defined pathways for the management of non-variceal upper GI haemorrhage and although the initial stages of this are most frequently managed by gastroenterologists, it is the responsibility of the surgical trainee to be aware of the appropriate protocols and evidence base. Where once commonplace, the elective surgical procedures described above are now almost only of historical interest, although many of the resectional techniques and their associated complications remain of pertinence with regard to surgery for upper gastro-intestinal malignancy. Surgical intervention for peptic ulcer disease is reserved almost exclusively for acute complications with procedures intended to deal only with the immediate problem. There is also a growing swell of interest in laparoscopic intervention in the acute setting, with evidence mounting of superior or at least equivalent outcomes. ◆

REFERENCES

1 Yuan Y, Padol IT, Hunt RH. Peptic ulcer disease today. *Nat Clin Pract Gastroenterol Hepatol* 2006; **3:** 80—9.

2 Lipof T, Shapiro D, Kozol RA. Surgical perspectives in peptic ulcer disease and gastritis. *World J Gastroenterol* 2006; **12:** 3248—52.

3 Marshall BJ, Warren JR. Unidentified curved bacilli in the stomach of patients with gastritis and peptic ulceration. *Lancet* 1984; **1:** 1311—5.

4 Shah R. Dyspepsia and *Helicobacter pylori*. *Br Med J* 2007; **334:** 41—3.

5 Primrose JN. Stomach and duodenum. In: Russell RCG, Williams NS, Bulstrode CJK, eds. Bailey and love's short practice of surgery. London: Hodder Arnold, 2004; 1026—1061.

6 Harbison SP, Dempsey DT. Peptic ulcer disease. *Curr Probl Surg* 2005; **42:** 346—454.

7 Love JW. Peptic ulceration may be a hormonal deficiency disease. *Med Hypotheses* 2008; **70:** 1103—7.

8 Dyspepsia: management of dyspepsia in adults in primary care. CG17. London: National Institute for Health and Clinical Excellence, 2004. Ref type: report.

9 Lau JY, Sung J, Hill C, Henderson C, Howden CW, Metz DC. Systematic review of the epidemiology of complicated peptic ulcer disease: incidence, recurrence, risk factors and mortality. *Digestion* 2011; **84:** 102—13.

10 Palmer K, Nairn M. Management of acute gastrointestinal blood loss: summary of SIGN guidelines. *Br Med J* 2008; **337:** a1832.

11 Barkun AN, Bardou M, Kuipers EJ, et al. International consensus recommendations on the management of patients with nonvariceal upper gastrointestinal bleeding. *Ann Intern Med* 2010; **152:** 101—13.

12 Dorward S, Sreedharan A, Leontiadis GI, Howden CW, Moayyedi P, Forman D. Proton pump inhibitor treatment initiated prior to endoscopic diagnosis in upper gastrointestinal bleeding. *Cochrane Database Syst Rev* 2006; (4): CD005415.

13 Leontiadis GI, Sreedharan A, Dorward S, et al. Systematic reviews of the clinical effectiveness and cost-effectiveness of proton pump inhibitors in acute upper gastrointestinal bleeding. *Health Technol Assess* 2007; **11:** iii-164.

14 Gluud LL, Klingenberg SL, Langholz SE. Systematic review: tranexamic acid for upper gastrointestinal bleeding. *Aliment Pharmacol Ther* 2008; **27:** 752—8.

15 Lau JY, Sung JJ, Lam YH, et al. Endoscopic retreatment compared with surgery in patients with recurrent bleeding after initial endoscopic control of bleeding ulcers. *N Engl J Med* 1999; **340:** 751—6.

16 Loffroy R, Rao P, Ota S, De Lin M, Kwak BK, Geschwind JF. Embolization of acute nonvariceal upper gastrointestinal hemorrhage resistant to endoscopic treatment: results and predictors of recurrent bleeding. *Cardiovasc Intervent Radiol* 2010; **33:** 1088—100.

17 Padia SA, Geisinger MA, Newman JS, Pierce G, Obuchowski NA, Sands MJ. Effectiveness of coil embolization in angiographically detectable versus non-detectable sources of upper gastrointestinal hemorrhage. *J Vasc Interv Radiol* 2009; **20:** 461—6.

18 Eriksson LG, Ljungdahl M, Sundbom M, Nyman R. Transcatheter arterial embolization versus surgery in the treatment of upper gastrointestinal bleeding after therapeutic endoscopy failure. *J Vasc Interv Radiol* 2008; **19:** 1413—8.

19 Moller MH, Adamsen S, Thomsen RW, Moller AM. Preoperative prognostic factors for mortality in peptic ulcer perforation: a systematic review. *Scand J Gastroenterol* 2010; **45:** 785—805.

20 Moller MH, Adamsen S, Thomsen RW, Moller AM. Multicentre trial of a perioperative protocol to reduce mortality in patients with peptic ulcer perforation. *Br J Surg* 2011; **98:** 802—10.

21 Bertleff MJ, Lange JF. Laparoscopic correction of perforated peptic ulcer: first choice? A review of literature. *Surg Endosc* 2010; **24:** 1231—9.

22 Sanabria AE, Morales CH, Villegas MI. Laparoscopic repair for perforated peptic ulcer disease. *Cochrane Database Syst Rev* 2005; (4): CD004778.

23 McAnena O, Joyce M. Classic operations on the upper gastrointestinal tract. In: Farquharson M, Moran B, eds. Farquharson's textbook of operative general surgery. London: Hodder Arnold, 2005; 257—284.

